



David W Seymour

Mital Patel and Martin F W-Y Chan

# Aesthetic Preview: A Novel Approach

**Abstract:** Planning the final aesthetic result of restorative treatment is a key skill needed by the clinician to ensure predictable success. This paper aims to review current techniques that may be used by clinicians for an aesthetic preview, whilst also highlighting a simple technique that may be readily utilized in practice.

**Clinical Relevance:** It is considered good practice to give patients an aesthetic preview of the end result prior to commencing active treatment. This article demonstrates the different techniques available and those that are easily utilized in general practice. The aesthetic preview is of benefit to both the clinician and technician in defining treatment goals and improving communication.

**Dent Update 2012; 39: 422–426**

The need for an aesthetic preview before commencing definitive treatment is well documented.<sup>1,2</sup> In this article we aim to review the several techniques that can be adopted, whilst highlighting an inexpensive, quick and simple method that can easily be used by the general dental practitioner. The development of computer software to aid an aesthetic preview further is a rapidly growing market, however, in this article we aim only to review the 3-dimensional, clinical techniques available.

Managing a patient's expectations is paramount when undertaking all aspects of restorative dentistry.<sup>3</sup> In certain areas, such as removable prosthetics, it is commonplace to show and discuss the final result with the patient prior to its construction. However, in fixed prosthodontics in particular, this is not always the case. Patients' demands are ever increasing and it is vital that they can visualize the final result, prior to the start of

treatment, whilst also allowing the dentist to highlight any limitations.

The techniques we aim to review are as follows:

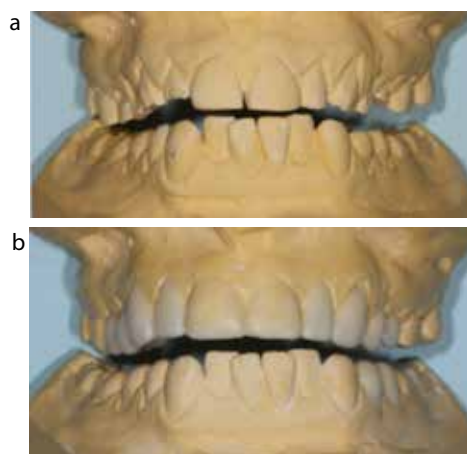
- Diagnostic wax-up;
- Addition of uncured composite;
- Use of black ink;
- Vacuum-formed splint delivery systems;
- Review of previous cases.

A novel technique commonly used in our department will be discussed at the end of the manuscript.

## Diagnostic wax-up

A technique traditionally favoured by many clinicians is the use of articulated study models and the diagnostic wax-up. It involves a lab technician adding wax to an articulated model of the patient's dentition (Figure 1). It allows the clinician to visualize the original dentition, restoration design, occlusal scheme and possible aesthetic outcomes.<sup>4</sup>

A common error when the technique is used by clinicians is to assume the lab will 'wax-up' the teeth in the optimal position required. It is vital for the clinician to prescribe tooth position, size, angulation and design of any prosthesis in detail. Close liaison with the lab is essential during this process.<sup>5</sup> It is also important to carry out appropriate reduction of the stone cast before addition of wax to avoid overcontouring and excessive bulk of any future restorations.



**Figure 1. (a, b)** Study models and diagnostic wax-up.

The wax-up can also mislead the clinician and patient into believing a result is achievable when, in reality, it is not; an example is not considering pulp anatomy when planning the wax-up.

This diagnostic wax-up can be used to form the cornerstone of discussions with the patient regarding the planned final outcome and is an invaluable tool.<sup>6</sup> However, alone it cannot give the patient an idea how the results will look intra-orally and thus has limitations.

The 'Kesling set-up',<sup>7</sup> more commonly used by orthodontists, is another technique that can show the patient an approximation of the final outcome. It involves a lab technician carefully removing

**DW Seymour**, BChD, MFDS RCS(Ed), Specialist Registrar in Restorative Dentistry, **M Patel**, BDS, BSc(Hons), MFDS RCS(Eng), Specialist Registrar in Restorative Dentistry, and **M F W-Y Chan**, BDS, MDS, FDS(Rest Dent) RCPS(Glasg), DRD, MRD RCSEd, Consultant in Restorative Dentistry, Leeds Dental Institute, Clarendon Way, Leeds, LS2 9LU, UK.

a tooth, or teeth, from a study model and replacing it in a more favourable position. Its use is most valuable when managing tooth movement to create space for restoration using bridges or implants (Figure 2).

### Addition of uncured composite resin

This is a simple technique that can be done chairside at the initial appointment. It allows the patient to visualize an approximation of the size, shape, position and, to some degree, the final shade that is achievable. Impressions of the composite 'mock-up' can be taken to provide a study model for future reference and to define the treatment goals.

It is obviously not possible to replicate the shape if tooth structure removal is needed. Further disadvantages relate to the use of composite, which can be costly if done regularly, and the difficulty in manipulating the composite quickly.

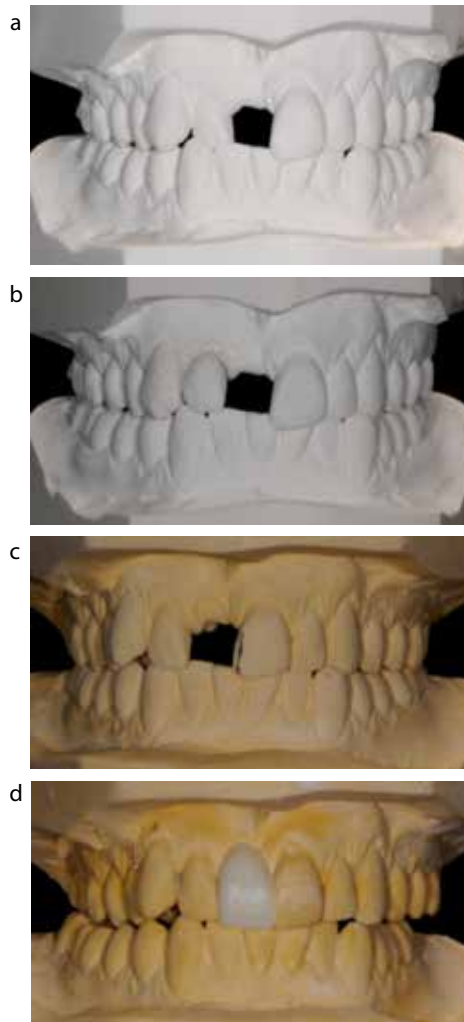
### Use of black ink

The application of water soluble ink to teeth was described by Nohl *et al* in 2002.<sup>1</sup> This technique is used where tooth reduction is being considered and involves the painting of the tooth structure that is being considered for removal with water soluble black ink. When viewed in the mouth the results are surprisingly useful.

### Vacuum-formed splint delivery systems

This technique directly follows on from the wax-up. Once the clinician and patient are happy with the wax-up, the next logical step is to review it intra-orally. There are various different techniques and materials that can be used and have been described in the literature.<sup>8,9</sup> The final choice of material generally depends on the length of time the clinician wants the 'mock-up' to be in place. The placement of stained, linked acrylic resin has been described to be used as a longer term 'mock-up' with which the patient can go home (Figure 3).

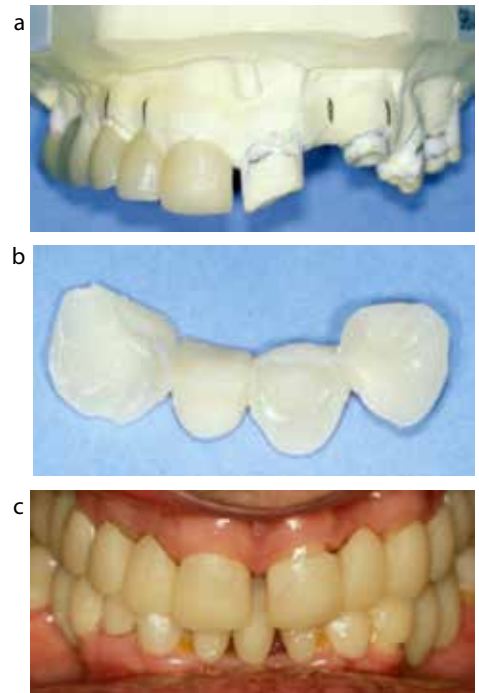
Generally, the most common technique is to use a vacuum-formed splint fabricated using a stone model copy of the definitive wax-up. Flowable composite is



**Figure 2.** (a) Pre-treatment study models. (b) Models following 'Kesling set-up'. (c) Models following orthodontic treatment, note how closely the models resemble the 'Kesling set-up'. (d) Models following definitive 'diagnostic wax-up' prior to implant placement.

then placed in the splint and placed over the teeth. Prior to this, petroleum jelly is placed over the teeth for easy removal of the 'mock-up' after its use. The composite is part cured and the excess is removed prior to definitive curing. Great care must be taken to limit composite leaking into the interdental spaces. The patient and clinician are then able to review the results (Figure 4). Photographs are taken and given to the patient and the 'mock-up' is removed before leaving. The splint can also be used as a tool during fixed prosthodontic preparation procedures as described by Curry in 1999.<sup>10</sup>

Advantages of this technique



**Figure 3.** (a) Linked acrylic resin 'mock-up' and underlying dentition on a study model. (b) Full view of linked acrylic resin 'mock-up'. (c) Acrylic resin 'mock-ups' in the mouth.

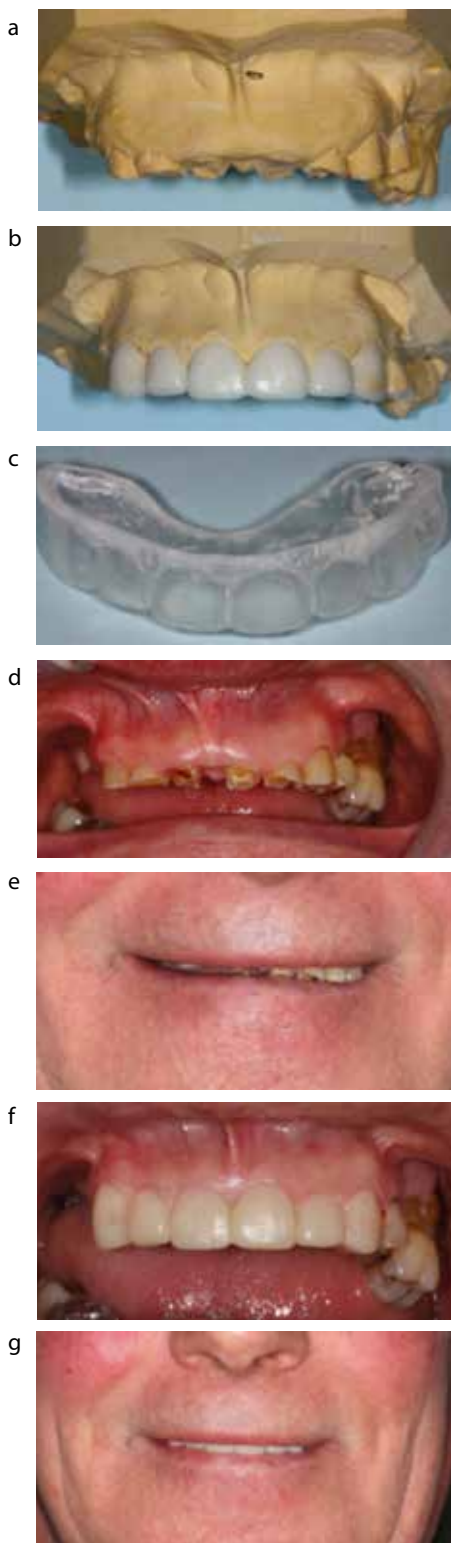
are that various shades of composite can be used and the results can be altered chairside to give the patient the final say in the result. The major problem with this technique is the cost involved as a diagnostic wax-up, vacuum-formed splint and composite are all needed.

### Review of previous cases

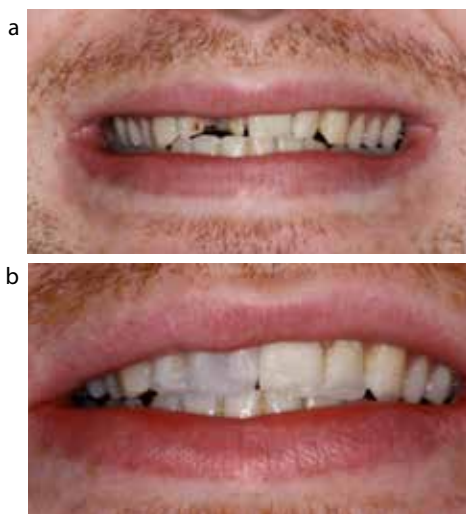Photographs of previous cases completed can also be an invaluable tool in giving the patient an idea of the final outcome. It is worth having photographs showing a range of treatment modalities and materials to review with the patient. It is also useful to show a mix of outcomes ranging from the ideal to the more realistic to prevent patients' expectations being raised to unattainable levels.

### A novel approach – 'the direct intra-oral wax-up'

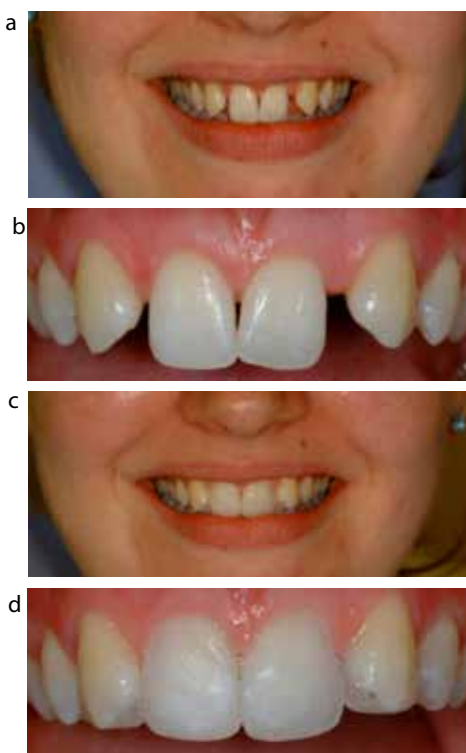
The method used widely in our department is the use of Orthocare® wax as a direct technique intra-orally. This technique has not been previously reported



**Figure 4.** (a) Initial upper study model. (b) 'Waxed-up' upper study model. (c) Vacuum-formed splint made from a stone copy of the wax-up. (d, e) Upper dentition pre-vacuum-formed 'mock-up'. (f, g) Upper dentition post vacuum-formed 'mock-up'.



**Figure 5.** (a, b) Direct intra-oral wax-up in a trauma case.



**Figure 6.** (a–d) Direct intra-oral wax-up in a space closure case.

in any other literature to our knowledge. The technique is simply to apply the wax to a dried, clean tooth and shape it using fingers, flat plastic or Wards carver to the desired shape (Figures 5 and 6). We have found Orthocare® wax specifically has the best properties for quick, intra-oral adaptation. The patient is then able to get

an insight into the treatment goals with respect to his/her own mouth and face.

The main advantage of this technique is its simplicity. It takes only a few minutes to complete, the costs are extremely low and it is an invaluable tool when discussing possible treatment options, especially at initial appointments. There are some disadvantages to this technique; specifically that it gives no insight into final shades of restorations. However, we have found that, in most situations, the shade is actually similar to the natural tooth as the wax is relatively translucent. Obviously, this technique can only be used whilst the patient is in the chair and there is no scope to try the 'mock-up' at home.

Again, it is possible to take an alginate impression of the intra-oral wax-up to provide a study model for future reference, if required. It is useful to take 'before' and 'after' clinical photographs to be used by the patient, clinician and technician. Some younger patients have found it useful to take photographs using their own mobile phones, so that the information is presented in a medium they are comfortable with and can access easily.

In our experience, this cheap, simple technique can often give the patient a good insight into the final outcome achievable, especially in the younger age group.

## Conclusion

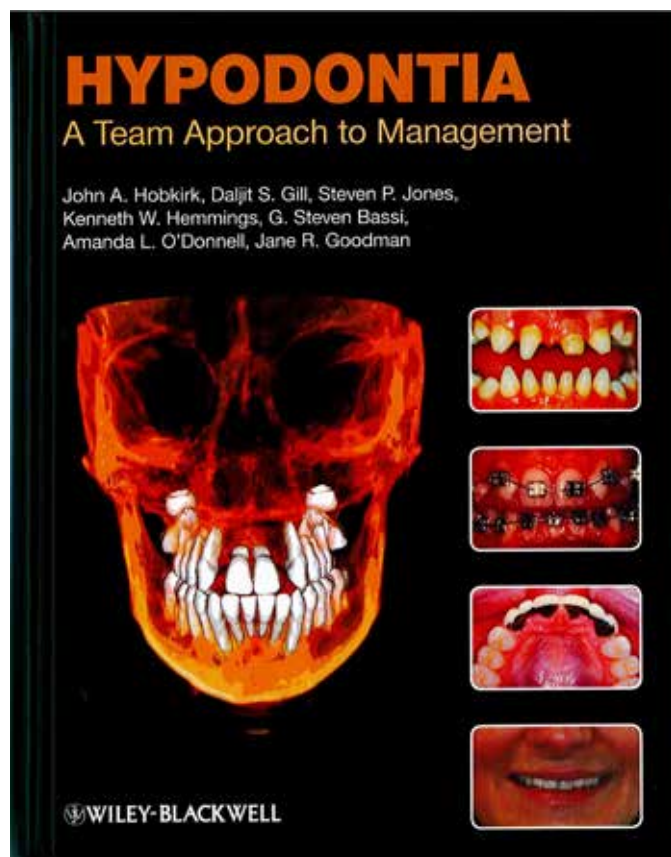
The aesthetic preview is an important part of gaining valid consent and in the treatment planning process. It is important that the patient can get an idea of the final result prior to commencing any treatment whenever this is possible. We have outlined the most common techniques employed and have shown examples of a very simple, yet effective technique using orthodontic wax which could easily be incorporated into general practice.

## References

1. Nohl FS, Steele JG, Wassell RW. Crowns and other extra-coronal restorations: aesthetic control. *Br Dent J* 2002 Apr 27; **192**(8): 443–450.
2. Reshad M, Cascione D, Magne P.

- Diagnostic mock-ups as an objective tool for predictable outcomes with porcelain laminate veneers in esthetically demanding patients: a case report. *J Prosthet Dent* 2008; **99**(5): 333–339.
3. Bloom DR, Padayachy JN. Smile lifts – a functional and aesthetic perspective. *Br Dent J* 2006 Feb 25; **200**(4): 199–203.
  4. Rudd KD. Making diagnostic casts is not a waste of time. *J Prosthet Dent* 1968; **20**(2): 98–100.
  5. Romeo G, Bresciano M. Diagnostic and technical approach to esthetic rehabilitations. *J Esthet Restor Dent* 2003; **15**(4): 204–216.
  6. Strassler HE. Planning with diagnostic casts for success with direct composite resin bonding. *J Esthet Dent* 1995; **7**(1): 32–40.
  7. Faltin RM, deAleida MA, Kessner CA, Junior KF. Efficiency, three dimensional planning and prediction of the orthodontic treatment with the Invisalign® system. A case report. *Roy Clin Orthod Dent Press* 2003; **2**: 61–71.
  8. Magne P, Magne M, Belser U. The diagnostic template: a key element to the comprehensive esthetic treatment concept. *Int J Periodont Restor Dent* 1996; **16**: 560–569.
  9. Simon H, Magne P. Clinically based diagnostic wax-up for optimal esthetics: the diagnostic mock-up. *J Calif Dent Assoc* 2008 May; **36**(5): 355–362.
  10. Curry F. Restorative alternative to Orthodontic treatment: a clinical report. *J Prosthet Dent* 1999; **82**: 127–129.

## Book Review



**Hypodontia: A Team Approach to Management.** By JA Hobkirk, DS Gill, SP Jones, KW Hemmings, GS Bassi, AL O'Donnell and JR Goodman. Oxford: Wiley-Blackwell, 2011 (200pp, £82.50 h/b). ISBN 978-1-4051-8859-3.

The developing dentition and craniofacial skeleton, the need to devise treatment plans which are patient-orientated, realistic and deliverable within the constraints of

recourses, plus the requirement of dentists to take account of new technologies and evidence for treatment outcomes, makes effective management of developmental hypodontia challenging. This book presents the subject in the light of these important aspects. The reader should not expect to find a recipe book on the management of hypodontia, for in all likelihood that could not, and should not, exist.

The scarcity of textbooks covering comprehensive management of hypodontia is not surprising given the need for close multidisciplinary

working and development of experience over an extended period of time; the authors amply fulfil this requirement. They all have association with a long-established specialist clinic dedicated to multidisciplinary management of patients with hypodontia, so are ideally placed to offer their expertise to this subject.

The book is divided into sections based on features of hypodontia followed by a final part describing management at

age-related stages of the dentition based on well explained principles and the evidence base, such as it is. The book structure and multidisciplinary authorship make it inevitable that the text contains repetition, and the introduction explains this feature as helpful to the reader to avoid needless movement between sections when reading. However, at times the repetition does seem a little cumbersome. There is appropriate emphasis placed on one of the commonest problems: the missing maxillary lateral incisor.

The book is a gold mine of source material on the subject, with evidence originating from the work of the author team justifiably presented. The management of hypodontia touches on just about every aspect of dental care, and well-chosen cases illustrate the diversity of presentations and treatments. This is an extremely useful reference and clinical guide for a wide range of practising dentists.

**Francis Nohl**  
Newcastle Dental Hospital

## CPD ANSWERS

JUNE 2012

- |            |             |
|------------|-------------|
| 1. C       | 6. A, C     |
| 2. B       | 7. D        |
| 3. A, B, C | 8. B, C     |
| 4. C       | 9. A, B, D  |
| 5. B, C    | 10. A, C, D |