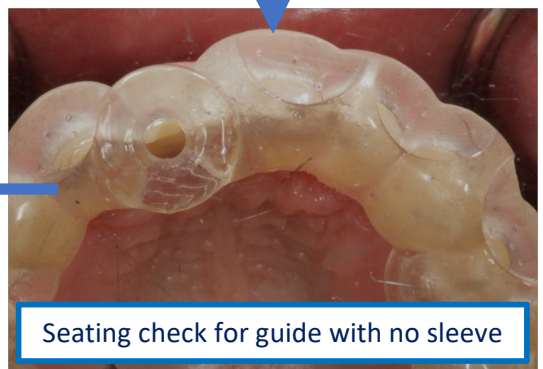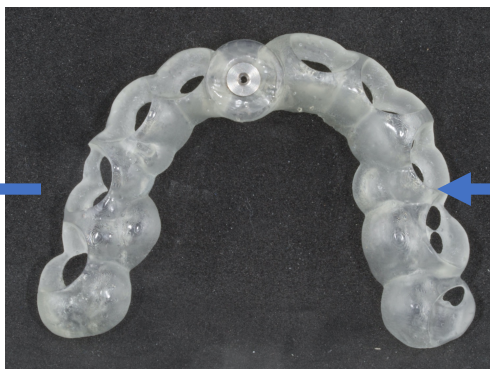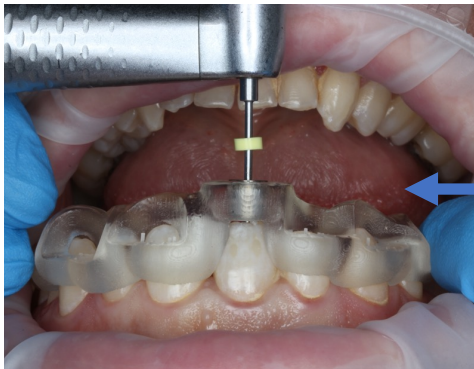
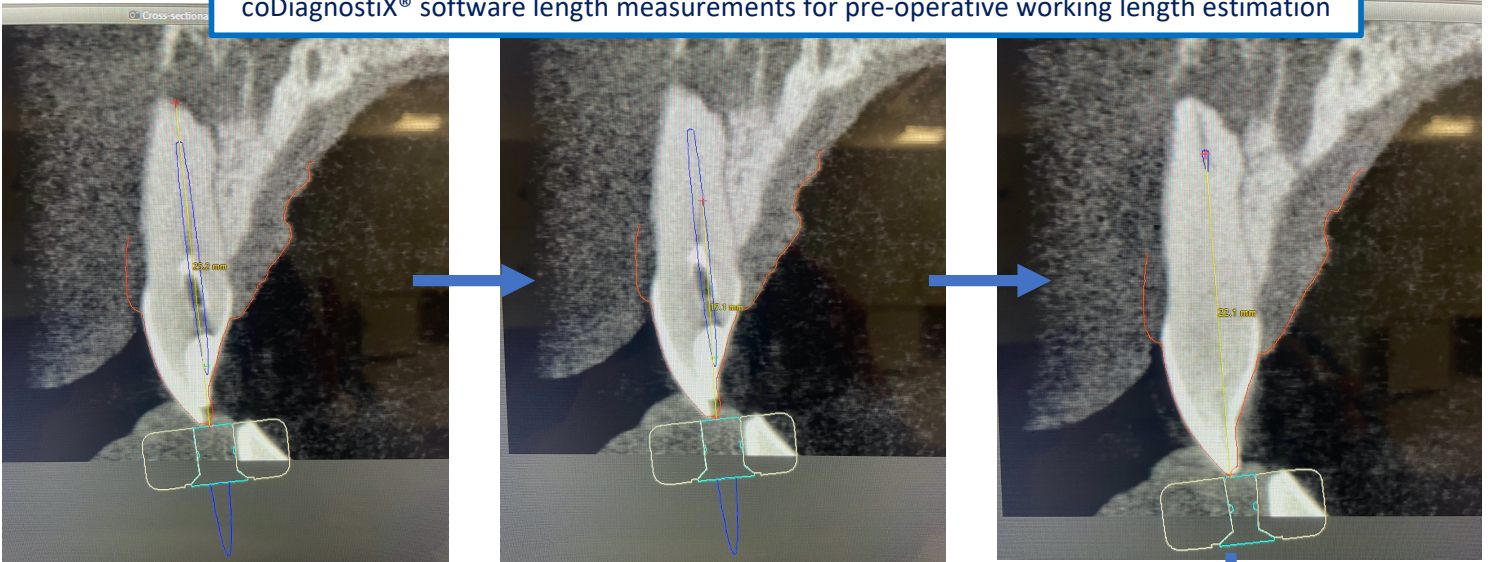


CASE 1

UR1 partial pulp canal obliteration secondary to trauma 15 years ago

coDiagnostiX® software length measurements for pre-operative working length estimation



Seating check for guide with no sleeve

Resultant undesired distal channel to desired patent apical third of canal

Rectified using conventional endodontics

Gutta percha / bioceramic sealer based obturation

