

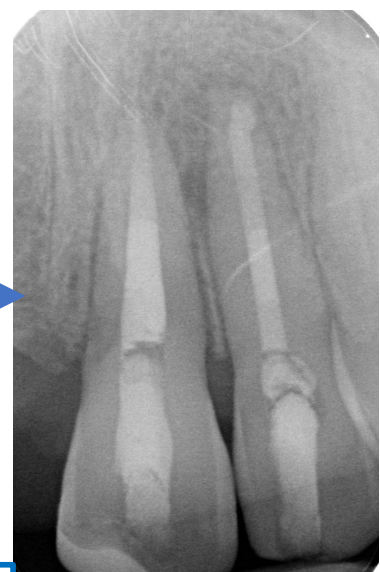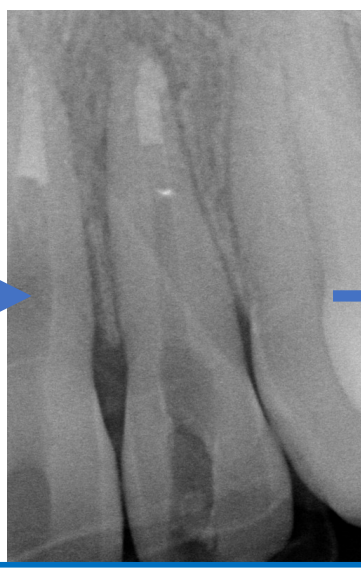
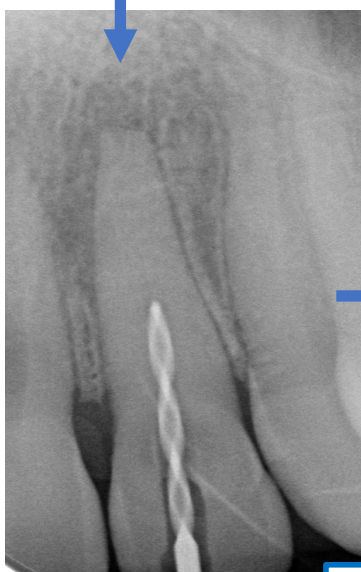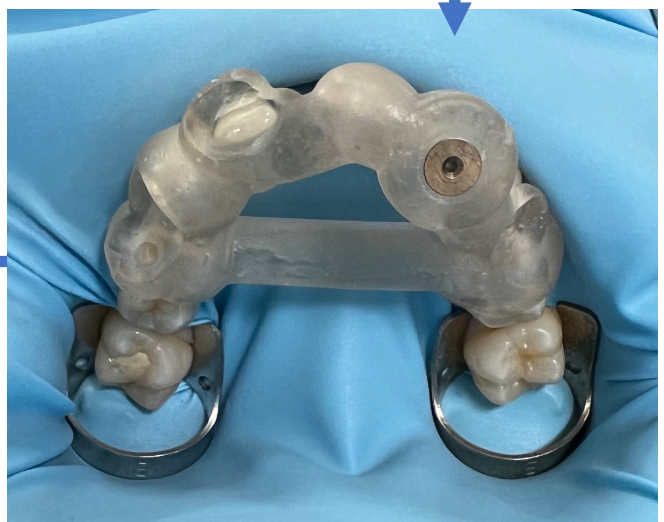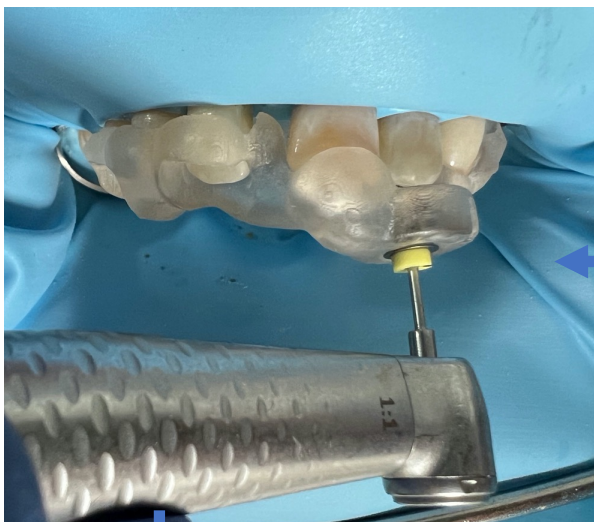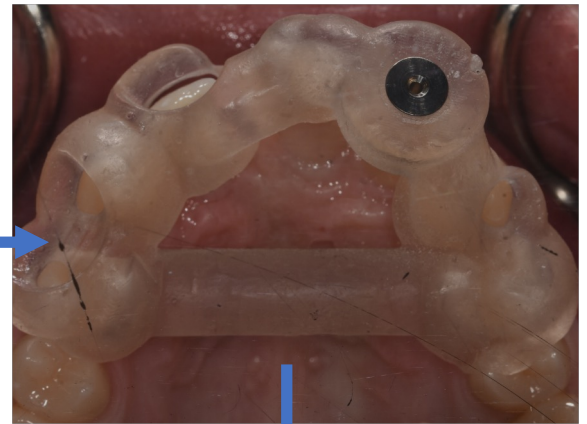
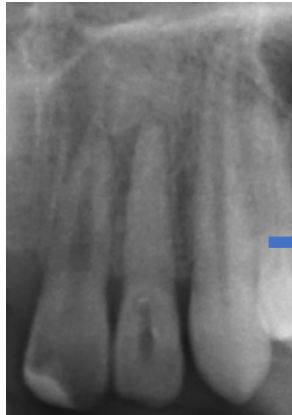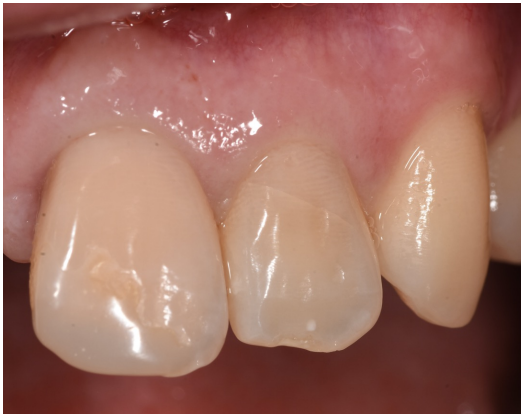Guiding a new path – a step by step guide to designing 3D printed guides in endodontics

Kajal B. Patel¹, Thomas Gill¹, Naren Thanabalan¹, Nahal Razaghi¹, Shakeel Shahdad², Mital Patel²

¹Specialty Registrar in Restorative Dentistry, Royal London Hospital, ²Consultant in Restorative Dentistry, Royal London Hospital

CASE 2

UL2 complete pulp canal obliteration to apex secondary to trauma



MTA plug to restore resultant open apex