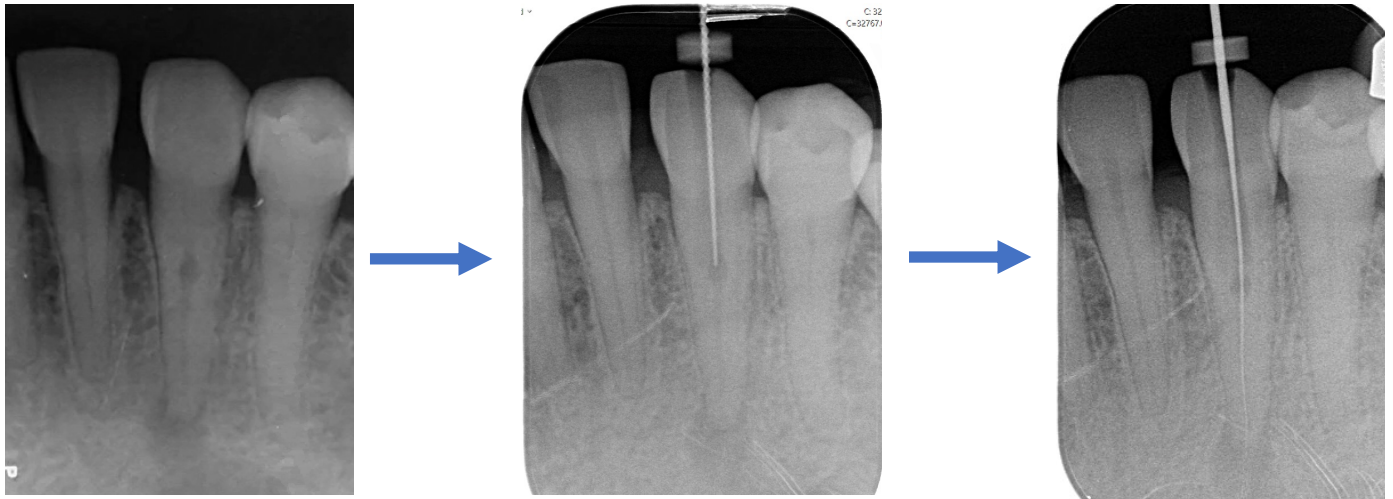
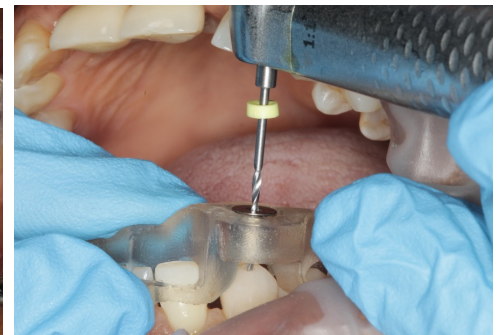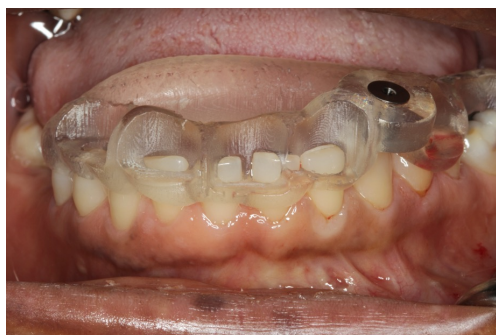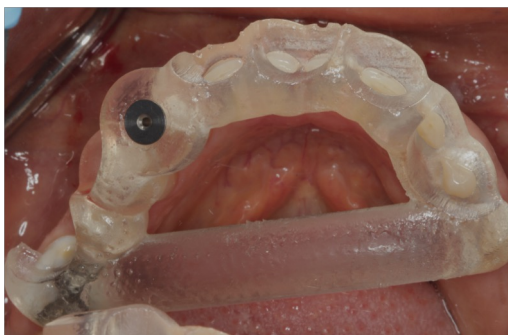
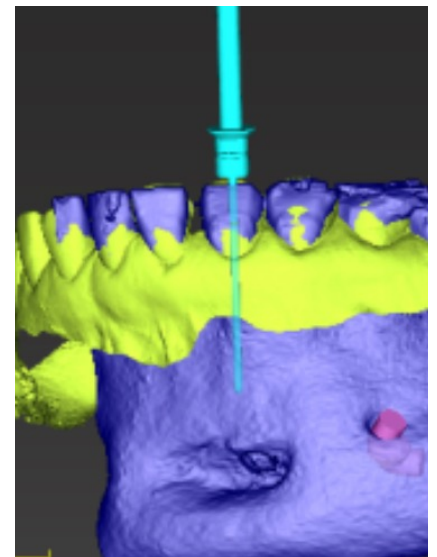

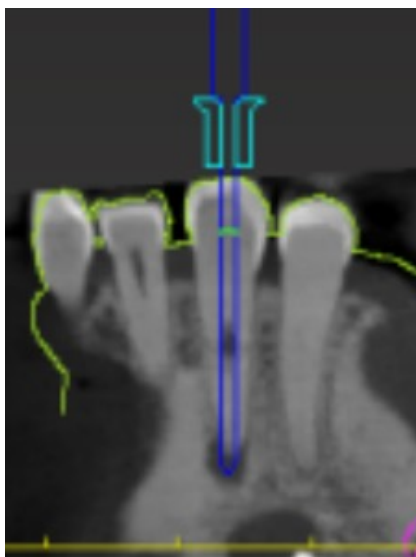


CASE 3

LL3 internal resorption with history of trauma approximately 20 years ago



coDiagnostiX[®] plan adjusted for endo sleeve to seat closer to incisal edge to improve accuracy



Guided drill not used to full working length, only used to extend in to resorption cavity (17.6mm) prior to the utilisation of conventional endodontics